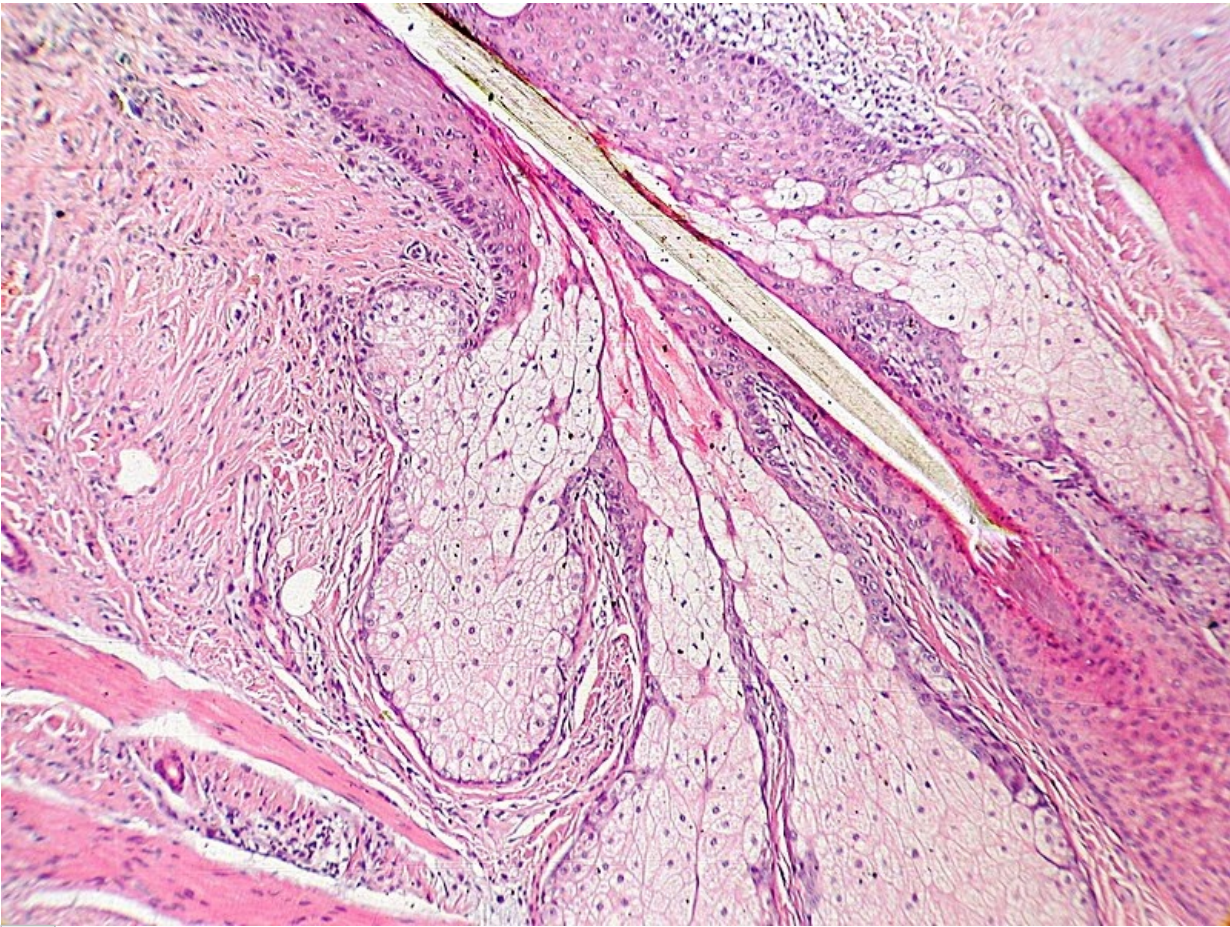


# Soubor:Insertion of sebaceous glands into hair shaft x10.jpg




This image can contain annotations.  
Move the mouse over the image to display.  
Size of this preview: 800 × 600 pixels.

Original file (2,048 × 1,536 pixels, file size: 1.04 MB, MIME type: image/jpeg)

 [Open in Media Viewer](#) 

This file is from Wikimedia Commons and may be used by other projects. The description on its file description page there is shown below.

<b>Description</b>	This is a hematoxylin and eosin stained slide at 10x of the insertion of sebaceous glands into hair shaft in a full, normal pilosebaceous unit, sectioned from tissue also found to have a benign intradermal nevus.
<b>Date</b>	18 October 2008
<b>Source</b>	Own work
<b>Author</b>	Kilbad
<b>Permission (Reusing this file)</b>	This work is not copyrighted, and permission for use on wikipedia is granted by me, the author

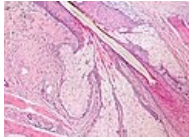


This work has been released into the **public domain** by its author, **Kilbad**. This applies worldwide.

In some countries this may not be legally possible; if so:  
*Kilbad grants anyone the right to use this work **for any purpose**, without any conditions, unless such conditions are required by law.*

## File history

Click on a date/time to view the file as it appeared at that time.

	Date/Time	Thumbnail	Dimensions	User	Comment
current	<b>17:45, 5 February 2015</b>		2,048 × 1,536 (1.04 MB)	wikimediacommons>Tilifa Ocaufa	improved colour and brightness

## File usage

The following 2 pages use this file:

- Kožní adnexa
- Mazové žlázy