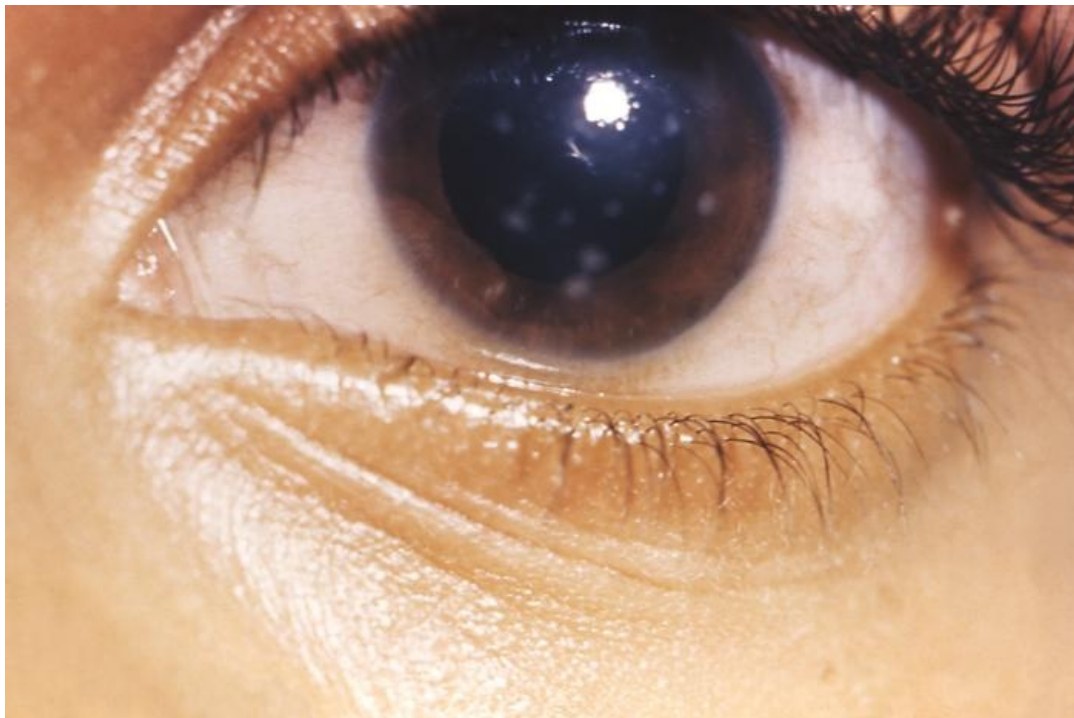


# Soubor:Keratitis.jpg




No higher resolution available.

Keratitis.jpg (700 × 465 pixels, file size: 36 KB, MIME type: image/jpeg)

<b>Popis</b>	Keratitis profunda u kongenitální syfilidy.
<b>Zdroj</b>	<a href="http://phil.cdc.gov/phil_images/20030716/32/PHIL_4149_lores.jpg">http://phil.cdc.gov/phil_images/20030716/32/PHIL_4149_lores.jpg</a> ( <a href="http://phil.cdc.gov/phil_images/20030716/32/PHIL_4149_lores.jpg">http://phil.cdc.gov/phil_images/20030716/32/PHIL_4149_lores.jpg</a> )
<b>Datum</b>	1973
<b>Autor</b>	CDC/ Susan Lindsley
<b>Licence</b>	Volné dílo nebo soubor, který nemá povahu autorského díla.

## File history

Click on a date/time to view the file as it appeared at that time.

	Date/Time	Thumbnail	Dimensions	User	Comment
current	<b>10:33, 13 June 2009</b>		700 × 465 (36 KB)	Nemekar (talk   contribs)	{{Soubor  popis = Keratitis profunda u kongenitální syfilidy.  zdroj = <a href="http://phil.cdc.gov/phil/home.asp">http://phil.cdc.gov/phil/home.asp</a>  datum = 1973  autor = CDC/ Susan Lindsley  licence = {{bez licence}} }} Kategorie:Mikrobiologie Kategorie:Neurologie

You cannot overwrite this file.

## File usage

The following 4 pages use this file:

- Syfilis
- Syfilis (klinický obraz)

- Treponema pallidum
- Vrozená syfilis

## Metadata

This file contains additional information, probably added from the digital camera or scanner used to create or digitize it.

If the file has been modified from its original state, some details may not fully reflect the modified file.