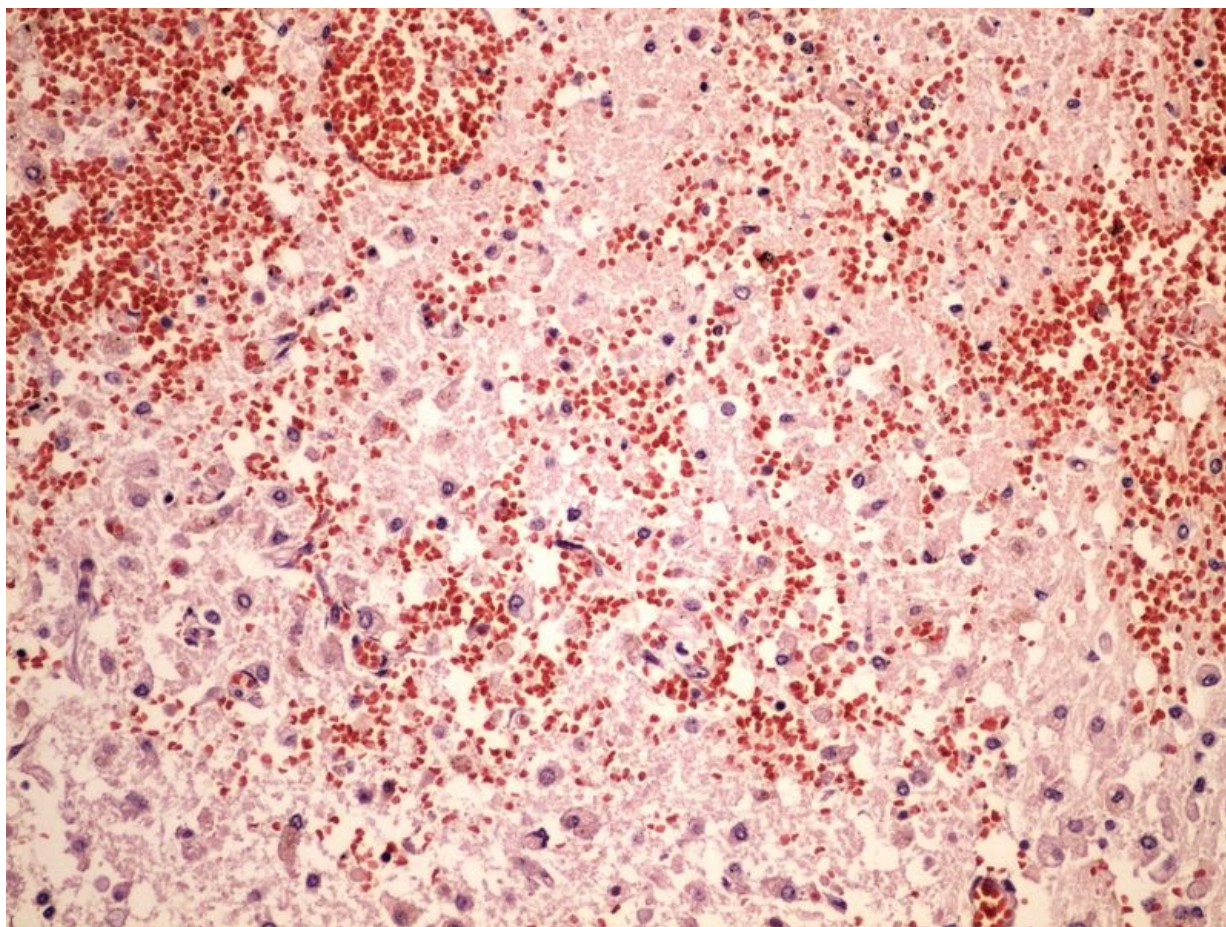


Soubor:Liquifactive necrosis kolikvacni nekroza 20x.jpg



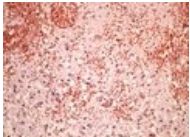
Size of this preview: 800 × 600 pixels.

Original file (2,560 × 1,920 pixels, file size: 3.21 MB, MIME type: image/jpeg)

| Popis | kolikvacni nekroza 20x - mikroskopický snímek |
|---------|---|
| Zdroj | vlastní dílo |
| Datum | 2013-10-28 |
| Autor | Patologie3LF |
| Licence | Vyhrazeno jen pro přímé užití na stránkách WikiSkripta.eu |

File history

Click on a date/time to view the file as it appeared at that time.

| | Date/Time | Thumbnail | Dimensions | User | Comment |
|---------|-------------------------------|---|-------------------------|--------------------------------|---------------------|
| current | 16:55, 31 October 2013 |  | 2,560 × 1,920 (3.21 MB) | Patologie3LF (talk contribs) | VicuñaUploader 1.18 |

You cannot overwrite this file.

File usage

The following 5 pages use this file:

- Infarkt
- Modul OZPP - Praktikum č. 2
- Modul OZPP - Praktikum č. 2 (zoom)
- Modul Obecné základy patologie a patofyziologie - Přehled preparátů
- Nekróza

Metadata

This file contains additional information, probably added from the digital camera or scanner used to create or digitize it.

If the file has been modified from its original state, some details may not fully reflect the modified file.