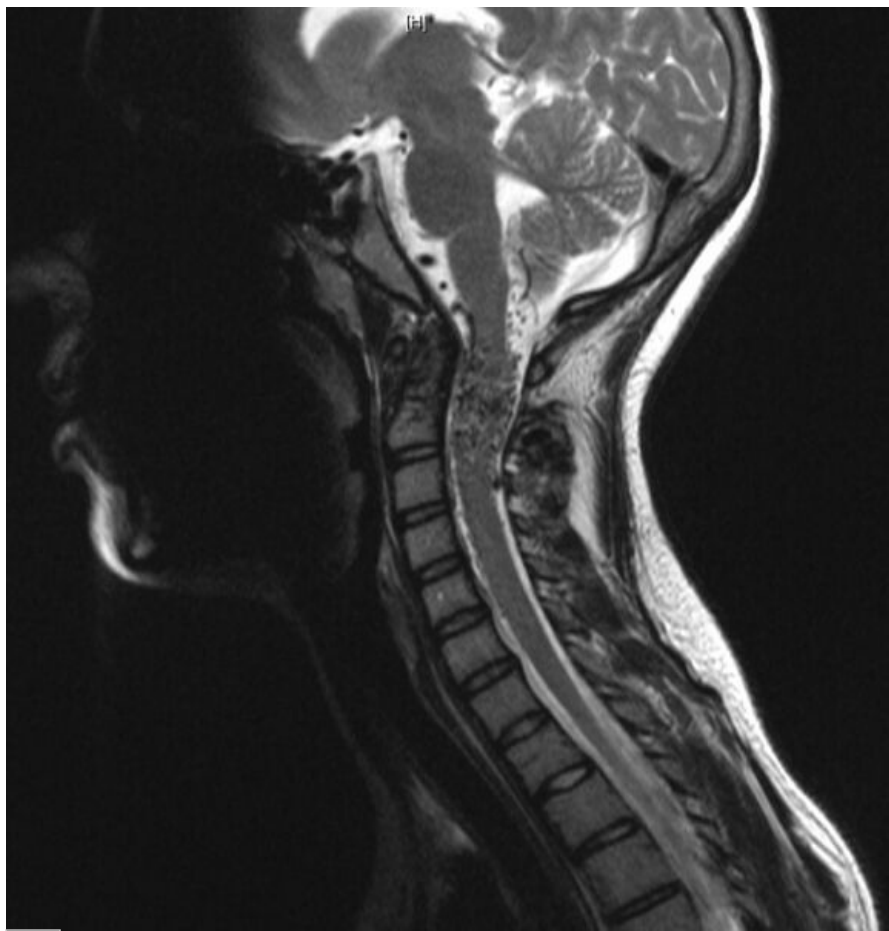

# Soubor:MRIT2 AVM.jpg



This image can contain annotations.  
Move the mouse over the image to display.  
Size of this preview: 577 × 600 pixels.

Original file (606 × 630 pixels, file size: 107 KB, MIME type: image/jpeg)



**Open in Media Viewer**



**Popis** MRI spinální AVM

**Zdroj** <https://radiopaedia.org/cases/spinal-arteriovenous-malformation-2?lang=us>

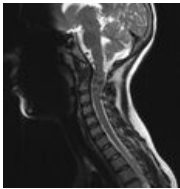
**Datum** 2021-06-26

**Autor** kolektiv Radiopaedia

**Licence** Volné dílo nebo soubor, který nemá povahu autorského díla.

## File history

Click on a date/time to view the file as it appeared at that time.

	Date/Time	Thumbnail	Dimensions	User	Comment
current	13:21, 26 June 2021		606 × 630 (107 KB)	AdELA (talk   contribs)	

You cannot overwrite this file.

## File usage

The following page uses this file:

- Arteriovenózní malformace