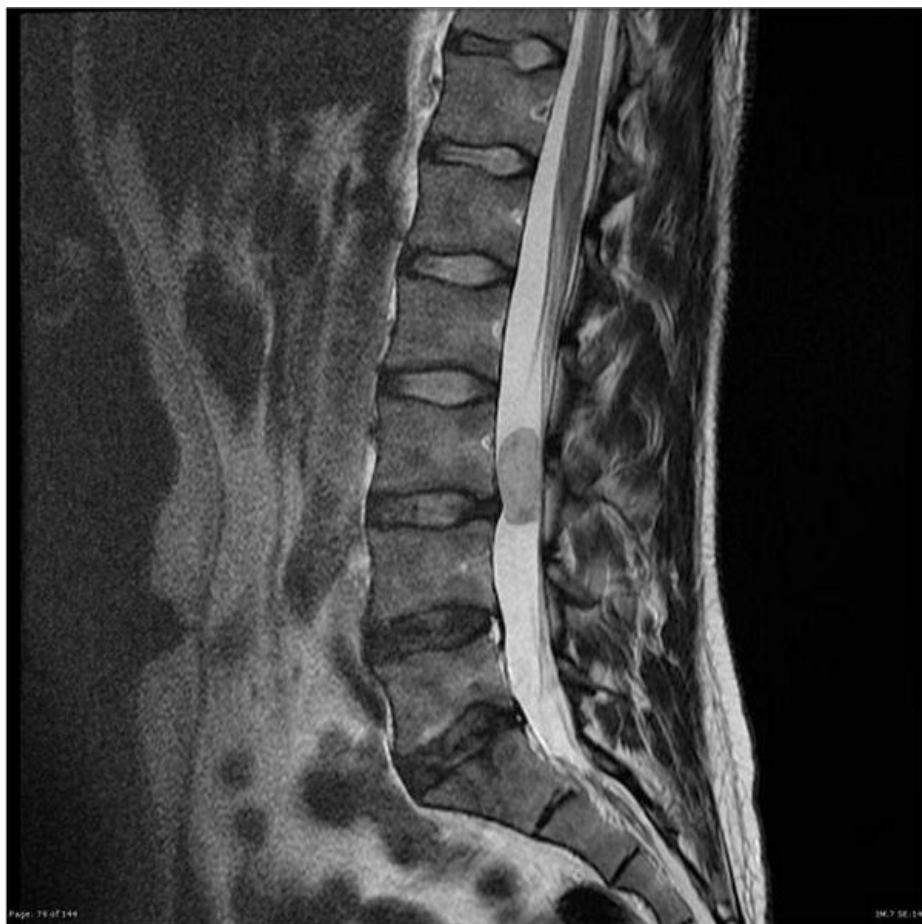

# Soubor:Myxo spinal.jpg



This image can contain annotations.  
Move the mouse over the image to display.  
Size of this preview: 600 × 600 pixels.

Original file (630 × 630 pixels, file size: 61 KB, MIME type: image/jpeg)

 **Open in Media Viewer** 

**Popis** MRI - myxopapilární ependymom

**Zdroj** <https://radiopaedia.org/articles/ependymoma?lang=us>


**Datum** 2021-04-08

**Autor** kolektiv Radiopaedia

**Licence** Volné dílo nebo soubor, který nemá povahu autorského díla.

## File history

Click on a date/time to view the file as it appeared at that time.

	Date/Time	Thumbnail	Dimensions	User	Comment
current	<b>07:56, 8 April 2021</b>		630 × 630 (61 KB)	AdELA (talk   contribs)	

You cannot overwrite this file.

## File usage

The following 3 pages use this file:

- Ependymom
- Nádory mozečku a IV. komory u dospělých
- Spinální nádory