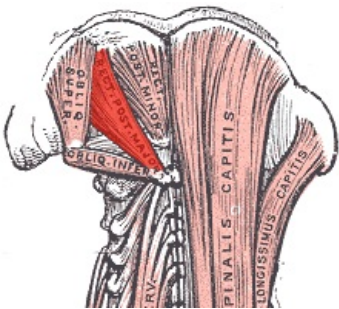


# Soubor:Rectus capitis posterior major.png



No higher resolution available.

Rectus\_capitis\_posterior\_major.png (223 × 198 pixels, file size: 33 KB, MIME type: image/png)

**Open in Media Viewer**

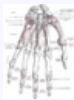This file is from Wikimedia Commons and may be used by other projects. The description on its file description page there is shown below.

**Popis kartičky** Rectus capitis posterior major

## Summary

<b>Description</b>	Rectus_capitis_posterior_major muscle
<b>Date</b>	17 December 2007
<b>Source</b>	modified from Image:Gray389.png
<b>Author</b>	Uwe Gille
<b>Permission (Reusing this file)</b>	PD
<b>Other versions</b>	Image:Gray389.png

Unless stated otherwise, this image is from the 20th U.S. edition of *Gray's Anatomy of the Human Body*, originally published in 1918 and therefore lapsed into the public domain. A copy of Gray's Anatomy can be found on Bartleby (<http://www.bartleby.com/107/>) and also on Yahoo! (<http://education.yahoo.com/reference/gray/>).



This image is in the **public domain** because it is a mere mechanical scan or photocopy of a public domain original, or – from the available evidence – is so similar to such a scan or photocopy that no copyright protection can be expected to arise. The original itself is in the public domain for the following reason:



This work is in the **public domain** in its country of origin and other countries and areas where the copyright term is the author's **life plus 100 years or fewer**.

---

This work is in the **public domain** in the United States because it was published (or registered with the U.S. Copyright Office) before January 1, 1929.

This file has been identified as being free of known restrictions under copyright law, including all related and neighboring rights. (<https://creativecommons.org/publicdomain/mar/1.0/deed.en>)

This tag is designed for use where there may be a need to assert that any enhancements (eg brightness, contrast, colour-matching, sharpening) are in themselves insufficiently creative to generate a new copyright. It can be used where it is unknown whether any enhancements have been made, as well as when the enhancements are clear but insufficient. For known raw unenhanced scans you can use an appropriate `{{PD-old}}` tag instead. For usage, see Commons:When to use the PD-scan tag.



Note: This tag applies to scans and photocopies only. For photographs of public domain originals taken from afar, {{PD-Art}} may be applicable. See Commons:When to use the PD-Art tag.

## Licensing

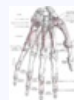This work is in the **public domain** in its country of origin and other countries and areas where the copyright term is the author's **life plus 70 years or fewer**.



**!** You must also include a United States public domain tag to indicate why this work is in the public domain in the United States. Note that a few countries have copyright terms longer than 70 years: Mexico has 100 years, Jamaica has 95 years, Colombia has 80 years, and Guatemala and Samoa have 75 years. This image may *not* be in the public domain in these countries, which moreover do *not* implement the rule of the shorter term. Honduras has a general copyright term of 75 years, but it *does* implement the rule of the shorter term. Copyright may extend on works created by French who died for France in World War II (more information), Russians who served in the Eastern Front of World War II (known as the Great Patriotic War in Russia) and posthumously rehabilitated victims of Soviet repressions (more information).

This file has been identified as being free of known restrictions under copyright law, including all related and neighboring rights. (<https://creativecommons.org/publicdomain/mark/1.0/deed.en>)

Unless stated otherwise, this image is from the 20th U.S. edition of *Gray's Anatomy of the Human Body*, originally published in 1918 and therefore lapsed into the public domain. A copy of Gray's Anatomy can be found on Bartleby (<http://www.bartleby.com/107/>) and also on Yahoo! (<http://education.yahoo.com/reference/gray/>).



This image is in the **public domain** because it is a mere mechanical scan or photocopy of a public domain original, or – from the available evidence – is so similar to such a scan or photocopy that no copyright protection can be expected to arise. The original itself is in the public domain for the following reason:



This work is in the **public domain** in its country of origin and other countries and areas where the copyright term is the author's **life plus 100 years or fewer**.

This work is in the **public domain** in the United States because it was published (or registered with the U.S. Copyright Office) before January 1, 1929.

This file has been identified as being free of known restrictions under copyright law, including all related and neighboring rights. (<https://creativecommons.org/publicdomain/mark/1.0/deed.en>)

This tag is designed for use where there may be a need to assert that any enhancements (eg brightness, contrast, colour-matching, sharpening) are in themselves insufficiently creative to generate a new copyright. It can be used where it is unknown whether any enhancements have been made, as well as when the enhancements are clear but insufficient. For known raw unenhanced scans you can use an appropriate {{PD-old}} tag instead. For usage, see Commons:When to use the PD-scan tag.



Note: This tag applies to scans and photocopies only. For photographs of public domain originals taken from afar, {{PD-Art}} may be applicable. See Commons:When to use the PD-Art tag.

## File history

Click on a date/time to view the file as it appeared at that time.

	Date/Time	Thumbnail	Dimensions	User	Comment
current	<b>01:30, 18 December 2007</b>		223 × 198 (33 KB)	wikimediacommons>Uwe Gille	{ {Information  Description=Rectus_capitis_posterior_major muscle  Source=modified from Image:Gray389.png  Date=12/17/2007  Author=Uwe Gille  Permission=PD  other_versions=Image:Gray389.png } } Category:Gray's Anatomy plates with help { {Gray's Anatomy p

## File usage

The following 2 pages use this file:

- Musculus rectus capitis posterior major
- Svaly zad (tabulka)