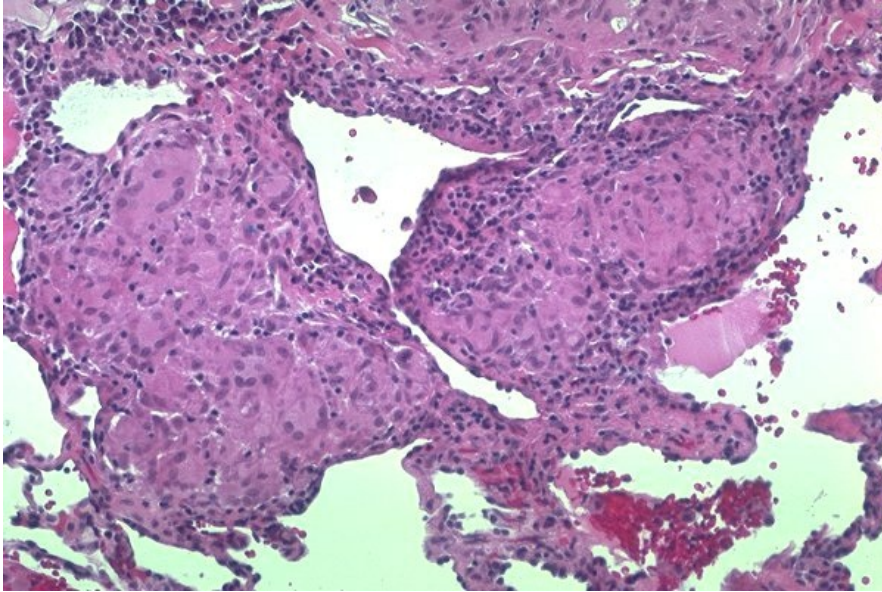


# Soubor:Sarcoid lunginv17.jpg



No higher resolution available.

Sarcoid\_lunginv17.jpg (600 × 401 pixels, file size: 84 KB, MIME type: image/jpeg)

<b>Popis</b>	Interstitial granulomas
<b>Zdroj</b>	<a href="http://granuloma.homestead.com/sarcoid_lung_microscopic.html">http://granuloma.homestead.com/sarcoid_lung_microscopic.html</a>
<b>Datum</b>	<i>nezadáno</i>
<b>Autor</b>	Yale Rosen, M.D.
<b>Licence</b>	Creative Commons NonCommercial-NoDerivs 3.0 Unported (CC BY-NC-ND 3.0) ( <a href="http://creativecommons.org/licenses/by-nc-nd/3.0/">http://creativecommons.org/licenses/by-nc-nd/3.0/</a> )

## File history

Click on a date/time to view the file as it appeared at that time.

	Date/Time	Thumbnail	Dimensions	User	Comment
current	<b>13:40, 18 October 2011</b>		600 × 401 (84 KB)	OK (talk   contribs)	{{Soubor  popis = Interstitial granulomas  zdroj = <a href="http://granuloma.homestead.com/sarcoid_lung_microscopic.html">http://granuloma.homestead.com/sarcoid_lung_microscopic.html</a>  datum =  autor = Yale Rosen, M.D.  licence = {{Zpracovat doplňit licenci}} }} Kategorie:patologie Kategorie:Obrázky

You cannot overwrite this file.

## File usage

The following page uses this file:

- Sarkoidóza (patologie)

## Metadata

This file contains additional information, probably added from the digital camera or scanner used to create or digitize it.

If the file has been modified from its original state, some details may not fully reflect the modified file.

