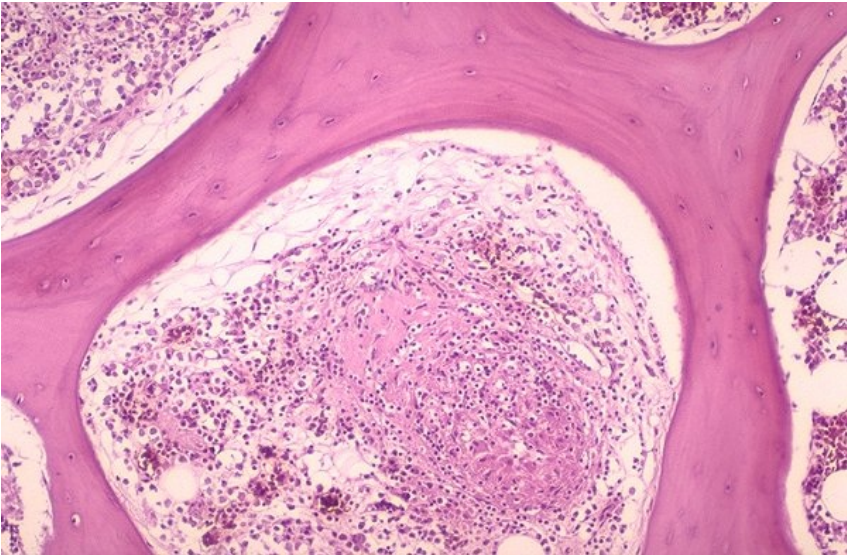


Soubor:Sarcoidosis extrapulmonary56.jpg



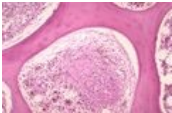
No higher resolution available.

Sarcoidosis_extrapulmonary56.jpg (600 × 392 pixels, file size: 80 KB, MIME type: image/jpeg)

Popis	sarkoidóza kostnej drene
Zdroj	http://granuloma.homestead.com/sarcoidosis_extrapulmonary.html
Datum	nezadáno
Autor	Yale Rosen, M.D
Licence	Creative Commons NonCommercial-NoDerivs 3.0 Unported (CC BY-NC-ND 3.0) (http://creativecommons.org/licenses/by-nc-nd/3.0/)

File history

Click on a date/time to view the file as it appeared at that time.

	Date/Time	Thumbnail	Dimensions	User	Comment
current	15:37, 3 November 2011		600 × 392 (80 KB)	JANKA (talk contribs)	{{Soubor popis = sarkoidóza kostnej drene zdroj = http://granuloma.homestead.com/sarcoidosis_extrapulmonary.html datum = autor = Yale Rosen, M.D licence = {{Zpracovat doplňit licenci}} }} Kategorie:patologie Kategorie:vnitřní lékařství

You cannot overwrite this file.

File usage

The following page uses this file:

- Sarkoidóza pohybového aparátu

Metadata

This file contains additional information, probably added from the digital camera or scanner used to create or digitize it.

If the file has been modified from its original state, some details may not fully reflect the modified file.