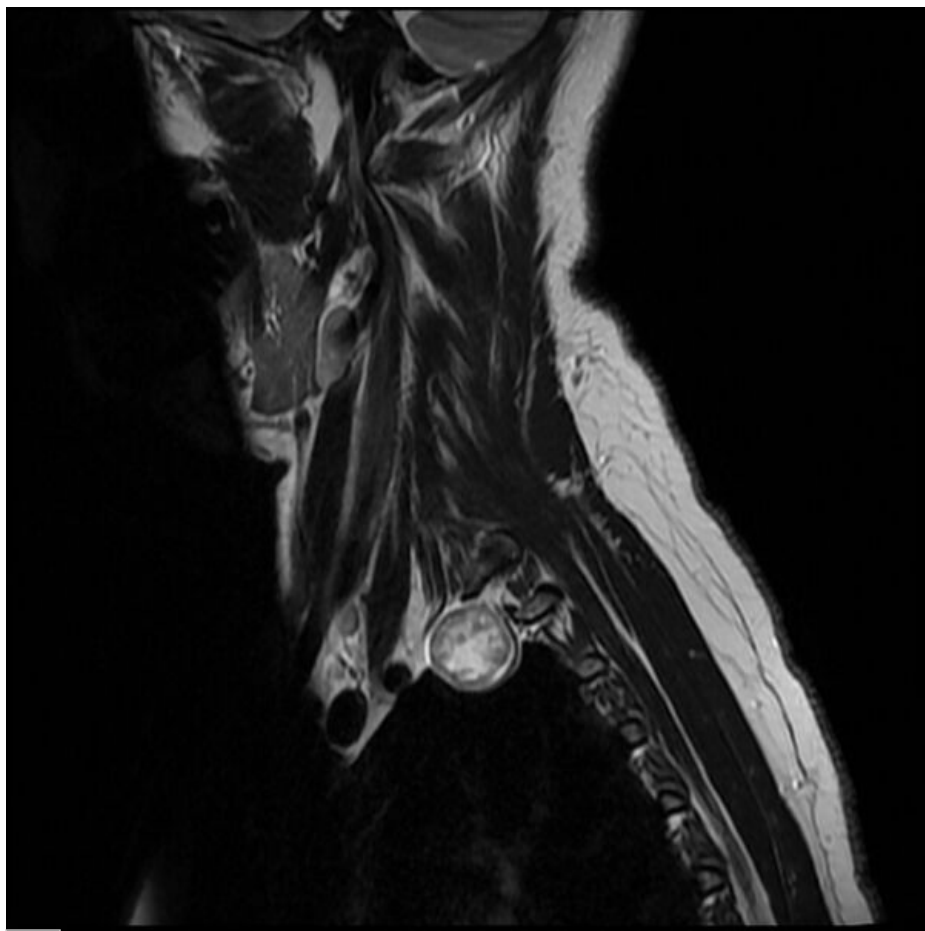


Soubor:T2sag intercostal schwannoma.jpg



This image can contain annotations.
Move the mouse over the image to display.
Size of this preview: 600 × 600 pixels.

Original file (630 × 630 pixels, file size: 129 KB, MIME type: image/jpeg)



Open in Media Viewer



Popis MRI schwannom interkostálního nervu

Zdroj <https://radiopaedia.org/cases/intercostal-nerve-schwannoma-1>

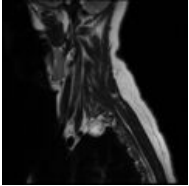
Datum 2021-05-20

Autor kolektiv Radiopaedia

Licence Volné dílo nebo soubor, který nemá povahu autorského díla.

File history

Click on a date/time to view the file as it appeared at that time.

	Date/Time	Thumbnail	Dimensions	User	Comment
current	19:48, 20 May 2021		630 × 630 (129 KB)	AdELA (talk contribs)	

You cannot overwrite this file.

File usage

The following page uses this file:

- Schwannom