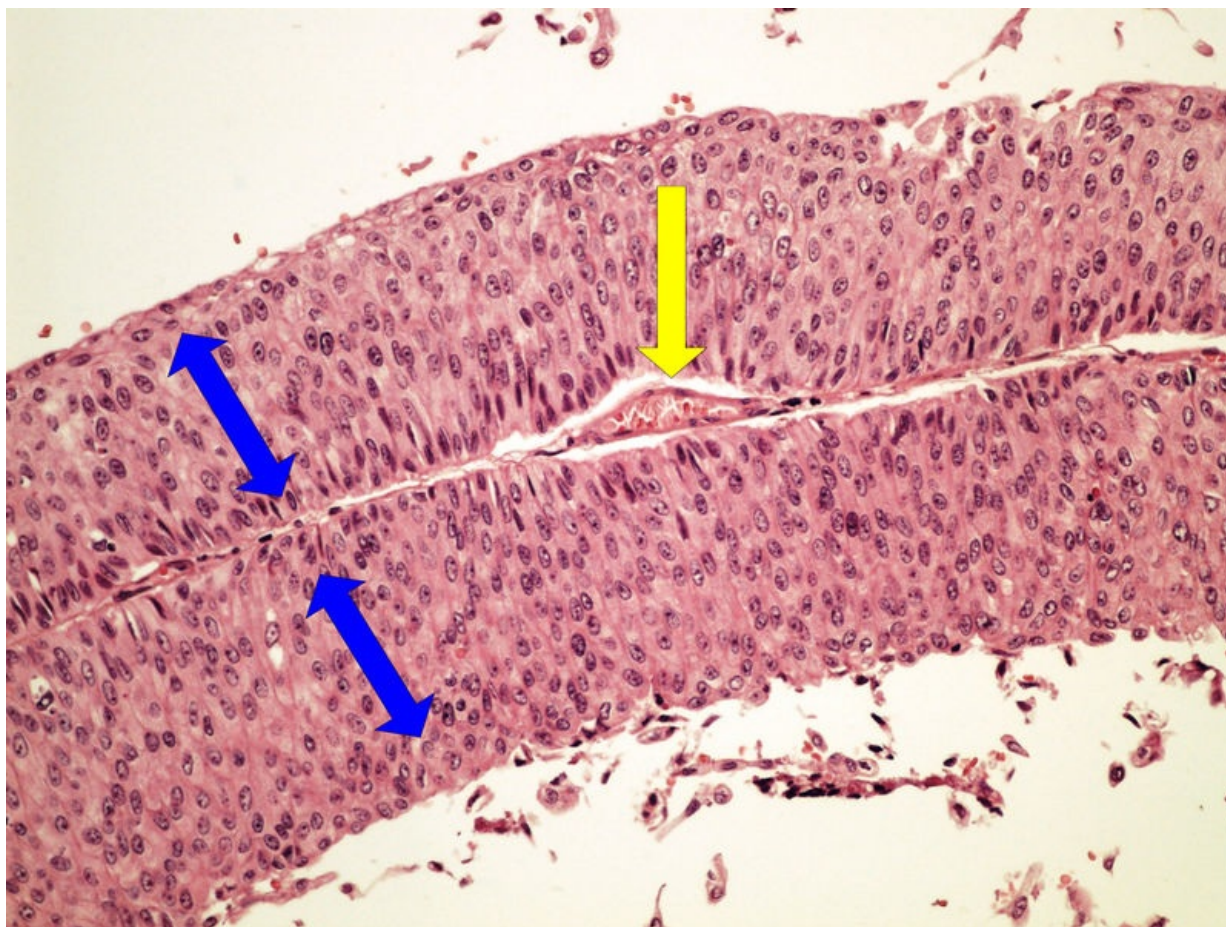


# Soubor:Z10-9 urothelial papillocarcinoma urotelialni papilokarcinom 20x oznaceno.jpg



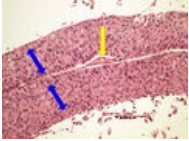
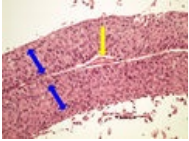
Size of this preview: 800 × 600 pixels.

Original file (2,560 × 1,920 pixels, file size: 4.84 MB, MIME type: image/jpeg)

<b>Popis</b>	<i>nežadán</i>
<b>Zdroj</b>	own work
<b>Datum</b>	2014-01-30
<b>Autor</b>	Patologie3LF
<b>Licence</b>	Vyhrazeno jen pro přímé užití na stránkách WikiSkripta.eu

## File history

Click on a date/time to view the file as it appeared at that time.

	Date/Time	Thumbnail	Dimensions	User	Comment
current	11:13, 22 October 2014		2,560 × 1,920 (4.84 MB)	Zef (talk   contribs)	správné označení epitelového krytu
	17:44, 29 January 2014		2,560 × 1,920 (3.73 MB)	Patologie3LF (talk   contribs)	VicuňaUploader 1.18

You cannot overwrite this file.

## File usage

The following 2 pages use this file:

- Modul OZPP - Praktikum č. 11
- Modul OZPP - Praktikum č. 11 (zoom)

## Metadata

This file contains additional information, probably added from the digital camera or scanner used to create or digitize it.

If the file has been modified from its original state, some details may not fully reflect the modified file.