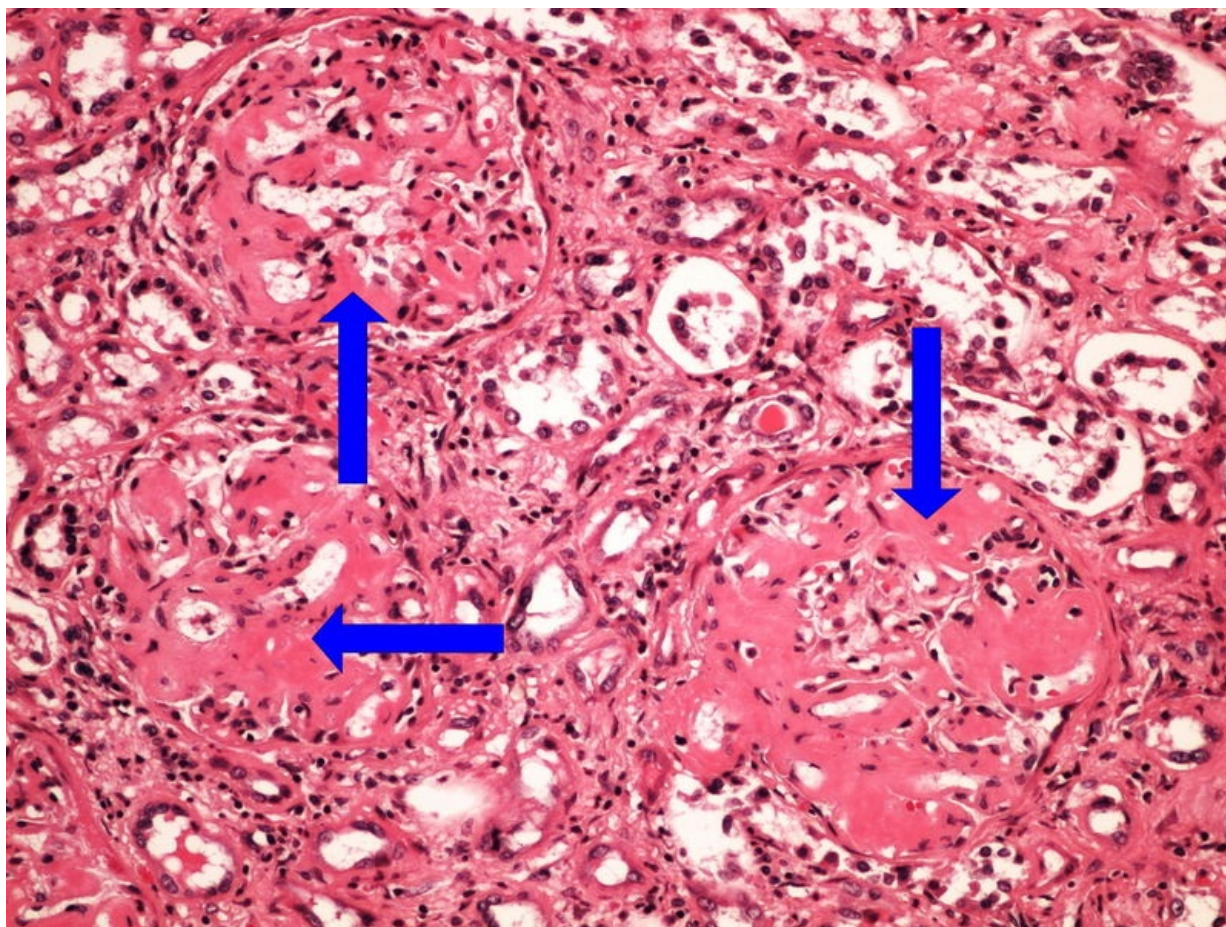


Soubor:Z3-12 amyloidosis kidney amyloidoza ledviny HE 20x oznaceno.jpg



This image can contain annotations.
Move the mouse over the image to display.
Size of this preview: 800 × 600 pixels.

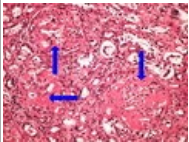
Original file (2,560 × 1,920 pixels, file size: 3.97 MB, MIME type: image/jpeg)

 [Open in Media Viewer](#) 

Popis	<i>nezadán</i>
Zdroj	vlastní dílo
Datum	<i>nezadáno</i>
Autor	Zef
Licence	Vyhrazeno jen pro přímé užití na stránkách WikiSkriptu.eu

File history

Click on a date/time to view the file as it appeared at that time.

	Date/Time	Thumbnail	Dimensions	User	Comment
current	09:34, 9 January 2014		2,560 × 1,920 (3.97 MB)	Zef (talk contribs)	VicuñaUploader 1.18

You cannot overwrite this file.

File usage

The following 2 pages use this file:

- Modul OZPP - Praktikum č. 3
- Modul OZPP - Praktikum č. 3 (zoom)

Metadata

This file contains additional information, probably added from the digital camera or scanner used to create or digitize it.

If the file has been modified from its original state, some details may not fully reflect the modified file.