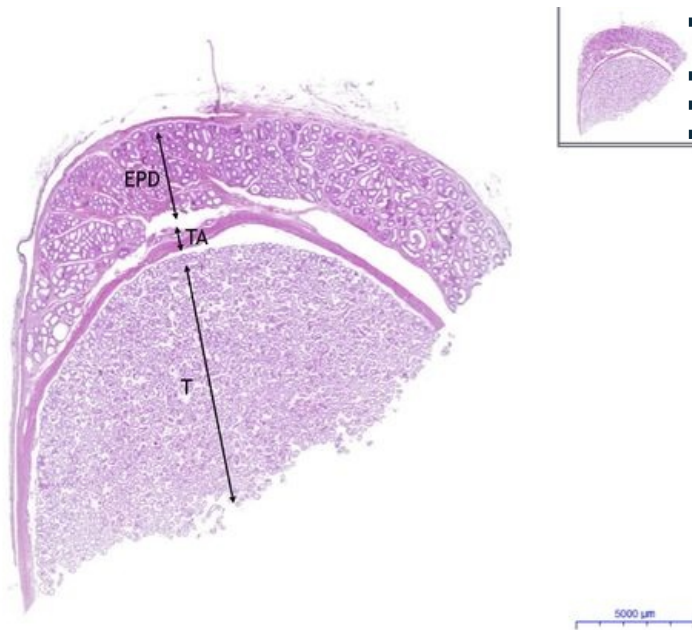


Varle / Testis - HE

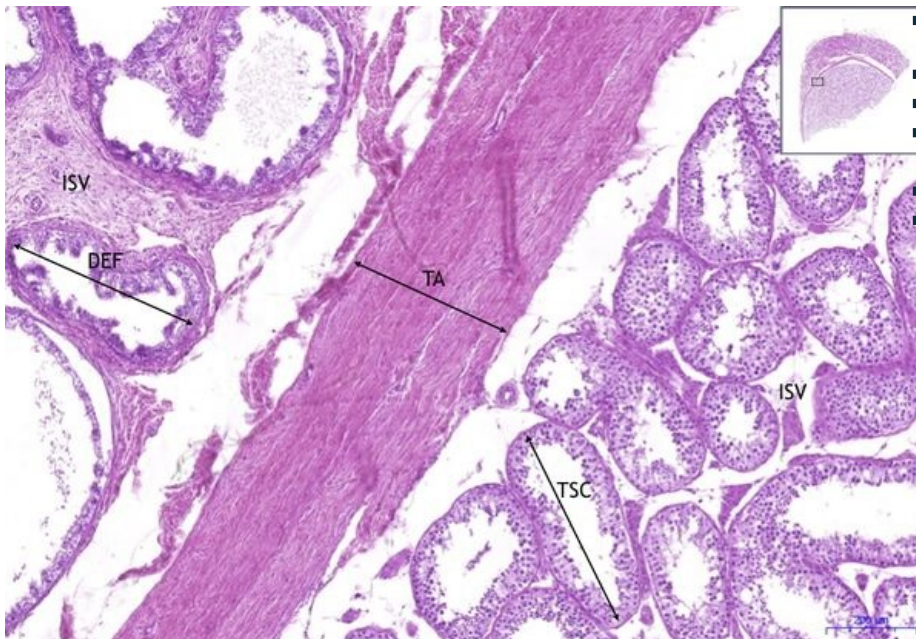
Testis, epididymis - HE, 0,3x



Testis, epididymis:

- 1) T - testis
- 2) TA - tunica albuginea
- 3) EPD - epididymis

Testis, epididymis - HE, 5x



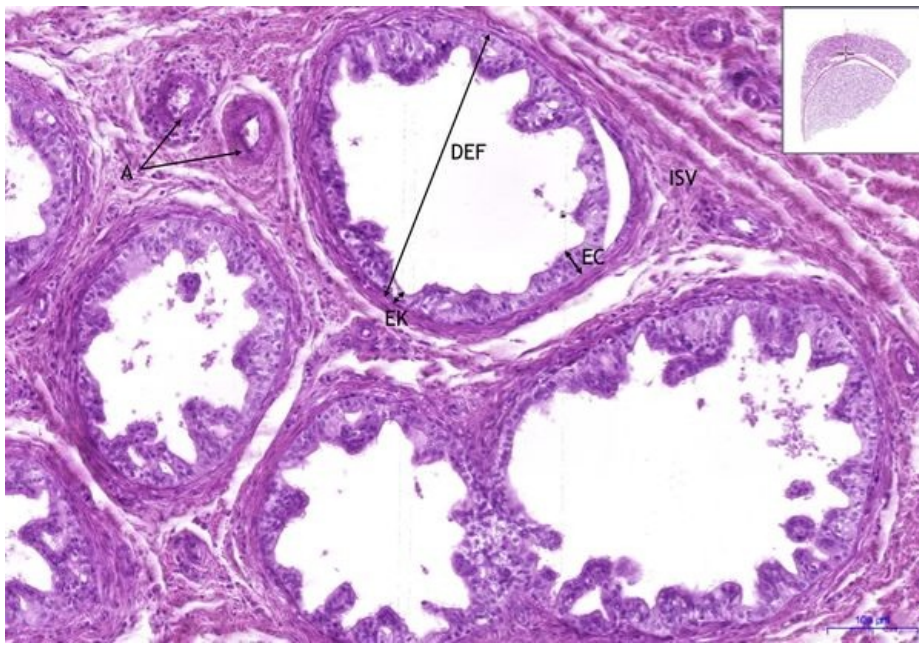
Testis, epididymis:

- 1) T - testis
- 2) TA - tunica albuginea
- 3) ISV - intersticiální vazivo / interstitial connective tissue
- 4) EPD - epididymis
- a) DEF - ductus efferens

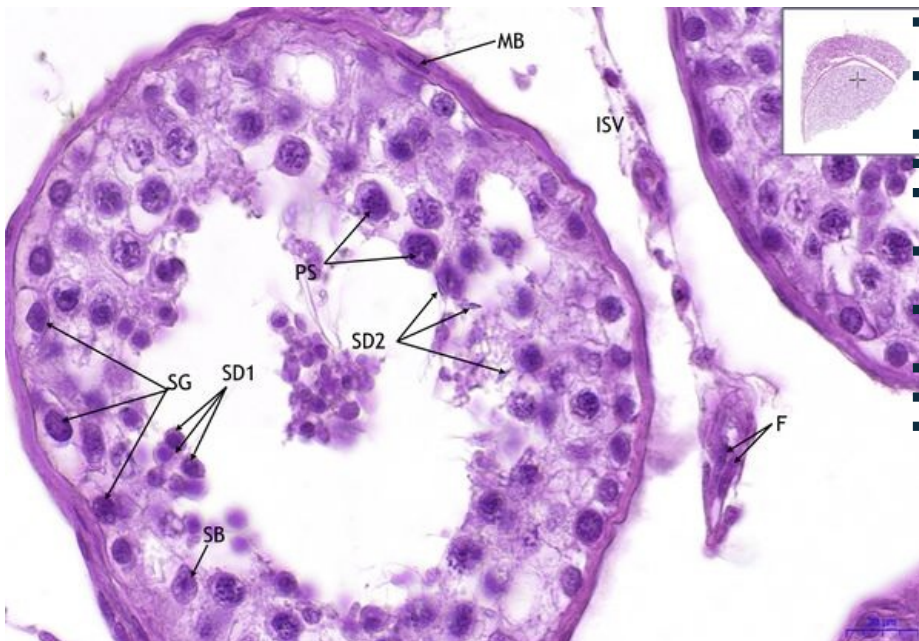
Testis, epididymis - HE, 10x

Testis, epididymis:

- 1) ISV - intersticiální vazivo / interstitial connective tissue
- 2) EPD - epididymis
- a) DEF - ductus efferens
- b) EK - kubický epitel / cuboidal epithelium
- c) EC - cylindrický epitel / columnar epithelium
- 2) A - artérie / arteries



Testis, epididymis - HE, 20x



Testis, epididymis:

- **1) ISV** - intersticiální vazivo / interstitial connective tissue
- **2) TSC** - tubuli seminiferri concorti
- **a) SG** - spermatogonie/spermatogonia
- **b) PS** - primární spermatocyty / primary spermatocytes
- **d) SD1** - rané spermatidy / early spermatid
- **e) SD2** - pozdní spermatidy / late spermatid
- **f) SB** - Sertoliho buňky / Sertoli cells
- **g) MB** - myeloidní buňka / myeloid cell
- **h) F** - fibroblast

Navigace

Navigace: Pohlavní systémy / Reproductive system

← Preparát č. 33

Seznam preparátů

Preparát č. 35 →